

Treatment of facial telangiectasias with a diode-pumped Nd:YAG laser at 532 nm

Daniel A Cassuto, Deborah M Ancona & Guglielmo Emanuelli

Authors:

Daniel A Cassuto MD
Deborah M Ancona MD
Guglielmo Emanuelli MD
Vascular Surgery Module,
Ospedale S Gerardo di Monza,
Italy

Received 30 May 2000
Revised 20 October 2000
Accepted 24 October 2000

Keywords:

532 nm – Nd:YAG – selective
photothermolysis –
telangiectasias – vascular laser

OBJECTIVE: Facial telangiectasias are a common cause of cosmetic concern. Current treatment modalities present various untoward effects and limits. The pulsed dye laser has been considered the gold standard in efficacy and safety; unfortunately it causes postoperative intracutaneous hematomata, discouraging many patients from undergoing this treatment. Several other vascular lasers (argon, tunable dye, copper, krypton, etc.) are disadvantaged by the risk of hypopigmented and atrophic scars.

MATERIALS AND METHODS: We assessed a recent powerful version of the potassium titanyl phosphate (KTP) 532 nm laser, which delivers sufficient energy in single pulses lasting 10–50 msec (DioLite 532; IRIDEX, Mountain View, CA, USA). Collateral damage is reduced while the heating of the vessel is slow enough to avoid explosive photothermolysis with

its associated purpura. Sixty six patients with facial telangiectasias were treated.

RESULTS: In 62/66 patients (93.9%) we achieved a 75–100% clearance of the lesions, while two treatments were needed to reach an acceptable clearance in the remaining 4/66 patients (6.1%). The eventual need for more sessions was well tolerated because the acceptable postoperative appearance allowed patients to continue normal business and social activities between treatments. No permanent complications or undesired effects were noted.

CONCLUSION: We conclude that this diode-pumped frequency-doubled Nd:YAG laser is an effective device for the treatment of facial telangiectasias, with a low profile of undesired effects that can be well tolerated by patients. *J Cutan Laser Ther* 2000; 2: 141–146

Introduction

Facial telangiectasias have been estimated to concern tens of millions of people worldwide.¹ These malformations have a multifactorial etiology, affecting mostly the Fitzpatrick I and II phototypes.² The other commonly contributing factors can be external, such as injudicious

exposure to ultraviolet rays (solar or artificial); iatrogenic, such as prolonged topical steroid treatment; estrogens; radiotherapy; conditions such as rosacea, hereditary hemorrhagic telangiectasia, collagen vascular diseases, idiopathic generalized telangiectasia; and in formerly hypertrophic scars. A certain degree of genetic predisposition is also present.

Telangiectasias are commonly defined as dilated capillaries, venules or arterioles with a diameter of 0.1–1.0 mm. While the mechanism of this dilatation is not completely understood, the abnormal structure of the vessels is attributed to actinic damage to their walls,

Correspondence: Daniel Cassuto; Via Bergamo 12, 20135 Milano, Italy.

E-mail: danicass@tin.it

Fax: +39 025469593

Original Research

causing them to lose some of their elasticity and to gradually become unable to resume their physiologic tonus.³

Various modalities have been employed to treat facial telangiectasias in the past, including electrodesiccation, cryosurgery and sclerotherapy, currently considered ineffective and unsafe. In the search for better results, a variety of laser systems have been tried.³ The earliest attempts were made with CO₂ and argon lasers. These were effective in treating facial telangiectasias, but the treated vessels did not absorb a significant part of the energy. The excess energy was delivered to the surrounding tissues, causing a disappointingly high incidence of scarring and dyspigmentation.¹ Following the theory of selective photothermolysis, hemoglobin was targeted as the chromophore to be destroyed by selective absorption of the energy, delivered with an adequate wavelength, energy density and pulse duration. The first pulsed lasers were specifically designed during the 1980s for the treatment of vascular malformations, especially around the peaks of light absorption by oxyhemoglobin at 418 and 577 nm.⁴ The safety and efficacy of the treatments were thus increased. The pulsed dye laser was the first to apply the theory of selective photothermolysis, removing facial telangiectasias safely and effectively with 1–2 passes. With a wavelength of 585 nm, spot size of 2–10 mm and a 0.45 msec pulse duration, it is also able to cover large areas in a relatively short time. Because of the large spot size, the handling technique does not require particular manual ability. The main disadvantage is the postoperative purpura, which lasts 1–2 weeks. The purpura is caused by the extravasation of the erythrocytes, due to the very fast pulse delivery that disrupts telangiectatic and normal capillaries. Attempts have been made to reduce this untoward effect by increasing the laser wavelength to 595–600 nm and the pulse duration to 1.5 msec. The purpura is also fluence-dependent, being more pronounced at higher energy densities. Lower fluences and longer pulse widths have reduced the purpura and its duration to about a week. However, these changes have also diminished the effectiveness of the treatments in many cases. These side effects deter many patients from seeking treatments.⁵

Several continuous, and quasi-continuous wave lasers, such as the tunable dye, copper vapor, copper bromide, krypton and potassium titanyl phosphate (KTP) lasers, have been used to treat facial telangiectasia. These lasers operate in a different way: the single vessels are traced with the laser beam using a spot of approximately the same diameter. This delivers the thermal energy only to the vessel and its closely adjacent tissues, resulting in photocoagulation of the vessel without extravasation of its contents, sparing normal capillaries. This mechanism of action does not cause purpura. However, these lasers demand a higher manual ability than the pulsed dye laser, and furthermore, the treatment is more time- and patience-demanding for the laser surgeon. As with other operator-dependent techniques, it carries the risk of inadvertent delivery of excessive thermal energy to the adjacent skin, which can result in linear hypopigmentation, hyperpigmentation, atrophic scars and other undesired effects. Their use on body areas other than the face is contraindicated.⁶

A more selective photothermolysis can be achieved by using a pulse duration close or equal to the thermal relaxation time (TRT) of the target vessels, commonly in the range of 10–50 msec for facial telangiectasias.⁴ The recent more powerful KTP lasers are also referred to as milliseconds Nd:YAG, to indicate their ability to vary the pulse duration according to the vessel diameter and location (e.g. face vs legs), which determine the TRT. This feature allows us to minimize the eventual collateral damage and the purpura at the same time. The absorption of green light at 532 nm by oxyhemoglobin is very high, compared to other wavelengths, resulting in a high extinction coefficient (Table 1).

The only theoretical disadvantage of the 532 nm light, compared to yellow lights, is its high absorption by melanin, which can interfere with treatment of darker skin types, and its more limited depth of penetration, caused by scattering across the dermis, compared to longer wavelengths.⁷ This study was conducted to evaluate the effectiveness and the incidence of undesired effects using a diode-pumped frequency-doubled Nd:YAG (Dio-Lite™ 532; IRIDEX, Mountain View, CA, USA) at 532 nm for the treatment of facial telangiectasias

Materials and methods

Sixty six patients with facial telangiectasias were included in this study: 55 females and 11 males, giving a ratio of 5:1. Ages ranged from 18 to 73 years (mean age = 46 years) with Fitzpatrick skin phototypes I, II and III. The classification of the lesions is listed in Table 2.

Wavelength	Laser	OEC (cm ⁻¹)
511 nm	Copper	320
514 nm	Argon	150
532 nm	KTP	320
568 nm	Krypton	330
578 nm	Copper	330
585 nm	Pulsed dye	320

Table 1
Oxyhemoglobin extinction coefficient (OEC) of vascular lasers.

Type of telangiectasia	Number of patients
Linear	12
Arborizing	36
Spider	7
Punctate	9
Macular telangiectasia	2
Total	66

Table 2
Distribution of treated lesions.

The etiology of the telangiectasias was mostly due to unjudicious exposure to ultraviolet (UV) rays by sunbathing or through the use of artificial UV lights, but rosacea and prolonged use of topical corticosteroids were also present. All treated vessels had a diameter of 1000 μm or less. Patients were treated in one or two sessions, according to the satisfaction with the clinical endpoint. No local or topical anesthesia was used. Prior to treatment any cosmetics were removed with a mild alcohol-free cleanser. The vessels were observed and treated under polarizing magnification (Seymour™ Light XL-2000 Illumination system). The DioLite™ 532 is a 6.8 kg device that uses a high power diode laser at 808 nm to optically pump a Nd:YAG crystal, which produces a 1064 nm light. The latter is focused onto a KTP crystal to double its frequency, obtaining a 532 nm wavelength. The spot size is varied by changing the handpiece. Handpieces are available in 200, 500, 700, 1000 and 1400 μm spot sizes. The pulse duration is adjustable between 1 and 100 msec, and the fluences range from 0.1 to 950 J/cm². Patients in this study were all treated by the same surgeon, and the parameters suggested by the manufacturer were selected. Fluence, spot size and the pulse duration were adjusted according to the varying vessel diameter, measured under the above-mentioned illumination system, and depth was judged by inspection under the same conditions. Passes were repeated when needed to reach the clinical endpoint of complete vessel blanching or visible intravascular coagulation. The majority of treatments were performed delivering fluences of 16–22.5 J/cm², using the 500 and 700 μm spots with pulse durations of 15–30 msec. The postoperative regimen included free use of make up and camouflage (as needed) and a skin recovery cream containing 67% thermal water (Laboratoires Dermatologiques Avène, Paris, France). Patients were examined at 1, 4 and 8 weeks after treatment for clinical inspection and detection of complications. Photographs were taken immediately before and 4 weeks after the end of treatment by the same photographer, using the same camera, illumination system, film, magnification and position. The photographs were examined by an independent observer excluded from the performance of the rest of the study. Clearance was eval-

uated as a percentage of the telangiectasias using a millimetric transparent grid. The clearance percentages were grouped in quartiles: 0–25%, 25–50%, 50–75%, 75–100%. At 8 weeks patients were also asked to complete a feedback form measuring treatment satisfaction.

Results

All patients had positive results, with 62/66 patients (93.9%) obtaining a 75–100% clearance of their telangiectasias. The remaining 4/66 (6.1%) had a 50–75% clearance but were satisfied with the results and did not request further treatment. Two of lower response group had used topical corticosteroids for years on their faces to treat skin allergies. The others had a macular telangiectasia. No response poorer than 50% clearance was noted after two treatments. The results are summarized in Table 3, together with the mean score obtained by the feedback questionnaires. All patients reported mild to moderate discomfort during treatment, that ceased immediately when the laser application was stopped. The results of the feedback questionnaires are indicated as average scores at the bottom of Table 3.

Postoperative undesired effects were immediate erythema and swelling that subsided within 2–10 hours, and microcrusting that resolved within a week. An example of a clinical result is shown in Figure 1. No permanent skin changes were noticed, besides the clearance of ephelides and other small senile and actinic small pigmentations. These were welcomed by the patients as it rejuvenated their look. Undesired effects were well tolerated and transient. The overall incidence of complications can be seen in Table 4.

Discussion

Selective photothermolysis is based on local absorption of light energy by target chromophores such as oxyhemoglobin in blood vessels, melanin in pigmented lesions and ink in tattoos. The absorption of the laser pulse by the

Clearance %	Linear	Arborizing	Punctate	Spider ang.	Macular
0–25	–	–	–	–	–
25–50	–	–	–	–	–
50–75	1 ^a	1 ^a	–	1	1
75–100	10	36	9	6	1 ^b
Satisfaction score	8/10	8/10	9/10	8/10	8/10

^a = patients after prolonged topical steroid treatment.

^b = case visible in Figure 1.

Table 3

Summary of clearance quartiles and patient satisfaction scores.

Original Research

Adverse effect	% of incidence	
Erythema	100	} transient
Swelling	100	
Microcrusting	83	
Dyspigmentation	0	
Scarring	0	
Burns	0	
Infections	0	

Table 4
Incidence of observed adverse effects.

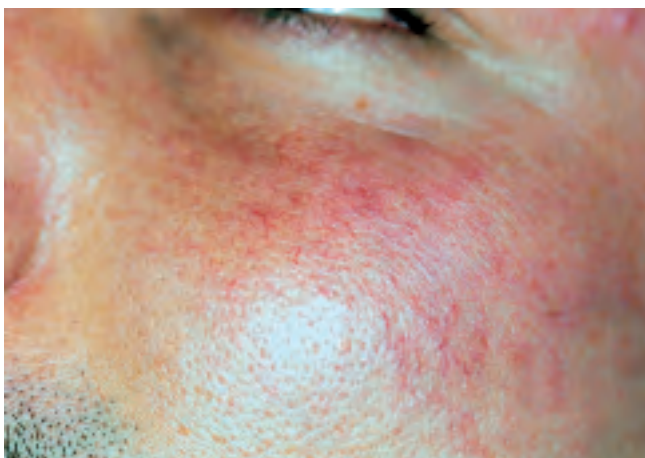chromophore increases its temperature, while passive cooling lowers it by heat conduction. In our case cooling is the combination of heat transfer to the skin and to the blood flowing in the vessels until they are photocoagulated. The thermal relaxation time (TRT) is defined as the time necessary for 50% cooling of a given chromophore, and depends upon the target size and shape.⁴ For maximum efficiency and selectivity the laser pulse duration should be approximately equal to or less than the thermal relaxation time. Short pulses, such as those delivered by the pulsed dye or the frequency doubled Q-switched Nd:YAG (FD QS Nd:YAG) lasers, tend to cause violent mechanical effects such as vessel rupture, resulting in intracutaneous hematomas and visible purpura, which is unacceptable for many potential patients. Thus the ideal pulse duration appears to be essentially equal to thermal relaxation time.⁴

Blood vessels with a 0.1 mm diameter have a TRT of about 5 msec, while a 0.3 mm vessel has a 40 msec TRT, and increasing the diameter to 1 mm brings its TRT up to 500 msec.⁴ The laser we tested has pulse duration variability between 0.1 and 100 msec, allowing us to choose the appropriate value and fluence according to the size

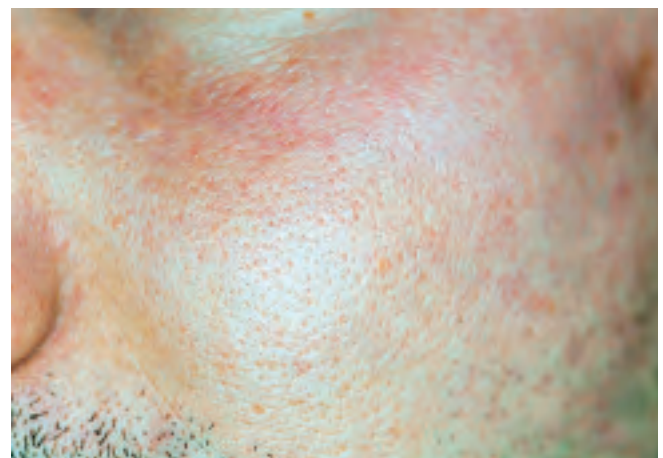
and location of the target vessel. In fact, high-flow vessels such as the perialar telangiectasias typically require higher fluences than expected by their dimensions. The clinical meaning of this technical feature is that the laser we used causes immediate disappearance of the telangiectasia instead of the purpura produced by other systems. The physical explanation of this phenomenon excludes active or passive vasoconstriction, since the latter cannot explain complete gross disappearance after KTP pulses. The proposed mechanism is gentle intravascular vaporization. Rupture of vessels from pulsed dye exposure is known to be caused by violent vaporization of blood within the vessel, occurring at about 140°C. With the longer KTP pulses, expansion of the intravascular 'steam bubble' during the laser pulse is less violent, and clearly does not rupture the vessel wall. The steam bubble is allowed to expand along the axis of the vessel, clearing the lumen and pushing a column of hot blood along the lumen. As the vessel cools according to its TRT, the vapor bubble condenses, collapsing the vessel wall. Thermal coagulation of the blood, now ejected well beyond the actual exposure site, creates an intravascular plug, leaving an empty, thermally damaged lumen at and around the site of laser exposure.

Whether this explanation is correct or not, the treatment is effective for facial telangiectasias (Figure 2), as other authors have shown, although in smaller groups of patients.^{1,2,8} This treatment modality is more acceptable for patients than pulsed dye laser treatment even when more than one session is required, since between sessions they can resume normal life without having to 'hide', and do not need any specific postoperative treatment. The potential hazard of intolerance to topical antibiotics is also eliminated.

Another potential advantage was the concomitant elimination of fine facial hyperpigmentation. This is another promising application of the diode-pumped FD Nd:YAG. The idea of treating pigmented lesions with this device is interesting since it respects skin integrity



(A)



(B)

Figure 1

(A) Fine telangiectasias of the malar eminence in a 28-year-old patient, who had regularly overexposed himself to artificial UV light over the years.
(B) At 4 weeks after treatment (1 pass, 19.6 J/cm², 500 μm).

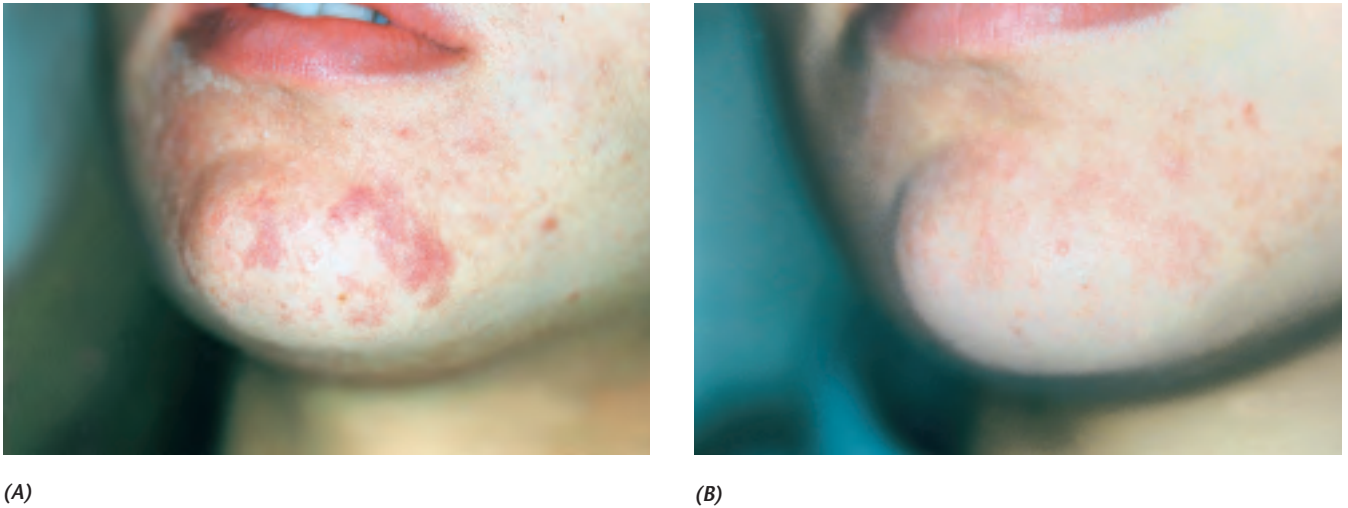


Figure 2
 (A) Macular telangiectasias of the chin in an 18-year-old patient (photograph taken 1 week before treatment). (B) Final result 8 weeks after treatment with the diode-pumped 532 nm laser.

and allows the immediate use of make up, unlike other existing laser systems, which remove the pigmentation together with the outer layers of the epidermis.

From the operator's point of view, some of the features of this diode-pumped FD Nd:YAG make life much easier than it was with the other vascular laser systems we have used for telangiectasias (copper vapor, pulsed dye and FD QS Nd:YAG). The frequent mirror collimation and cleaning, the dye refilling, the overheating of the machine and the room, the need for specialized personnel to install the system and the frequent disappointing shut-downs that we had experienced have all been eliminated by this compact, solid state, lightweight device, that can be moved very easily between different rooms or shared by different offices if needed. We found the fiberoptics handpiece easy to handle. Being connected through a thin fiberoptic cable instead of a mechanical optic arm like in other systems, it allows a great effortless freedom of movements, which is very important in manually tracing vessels smaller than 1000 μm . The millisecond 532 nm laser can also be effective in leg telangiectasias, where higher fluences and longer pulse duration are required, and the risk of scarring is higher.⁸⁻¹⁰

The disadvantages of the system are mainly due to the properties of 532 nm light, which is more highly absorbed by melanin than longer wavelengths, with a consequent increased risk of epidermal damage, especially with darker phototypes. Burns and consequent hyper- or hypopigmentation can be caused, especially when overlapping pulses are delivered. This explains the high incidence of microcrusting that we experienced, together with the absence of permanent skin damage, probably due to the particular tolerance properties of facial skin. However, particular attention must be used to avoid

overlap of treatment spots in scarring prone areas such as the upper lip, mandibular line and lateral neck skin. For treating facial skin, cooling is typically not needed. If desired a waterbased gel can be used as a heat sink for added safety and comfort. For treating facial telangiectasia, active cooling handpieces can often be large, bulky and make treatment difficult, particularly around the nose. After-market active skin cooling can be used with the diode-pumped FD Nd:YAG to make the system more suitable to treat leg telangiectasias. The 532 nm laser light also penetrates less deeply in tissue than longer wavelengths owing to its scattering across the skin, so that its efficiency in treating deeper telangiectasias is not equal to lasers emitting longer wavelengths.

Conclusion

Recent technologies have made the application of the selective photothermolysis more precise and adjustable, helping us to eliminate some undesired effects that deterred patients from accepting treatments. Facial telangiectasias were treated with a diode-pumped FD Nd:YAG laser with good results and safety. Patients reported general satisfaction from the treatment, as did the staff as far as the operating conditions were concerned. The low side effects profile made this kind of laser treatment more acceptable than treatment with a pulsed dye laser. Although promising preliminary results have been reported also for leg telangiectasias, at the moment this treatment modality should be restricted to selected indications such as fine matting and 'needle phobic' patients to replace sclerotherapy.

*Original Research***References**

1. Silver BE, Livshots YL. Preliminary experience with the KTP/532 nm laser in the treatment of facial telangiectasia. *Cosmet Dermatol* 1997; **9**: 61–4.
2. Goldberg DJ, Meine JG. A comparison of four frequency doubled Nd:YAG (532 nm) laser systems for treatment of facial telangiectases. *Dermatol Surg* 1999; **25**: 463–7.
3. Goldman MP, Bennett RG. Treatment of facial telangiectasia with sclerotherapy, laser surgery and/or electrodesiccation: a review. *J Am Acad Dermatol* 1987; **17**: 167–82.
4. Anderson RR, Parrish JA. Microvasculature can be selectively damaged using dye lasers: a basic theory and experimental evidence on human skin. *Lasers Surg Med* 1981; **1**: 263–76.
5. Raulin C, Weiss RA, Schonemark MP. Treatment of essential telangiectasias with an intense pulsed light source (PhotoDerm VL). *Dermatol Surg* 1997; **23**: 941–5.
6. Hruza GJ. Commentary to Treatment of essential telangiectasias with an intense pulsed light source (PhotoDerm VL). *Dermatol Surg* 1997; **23**: 945–6.
7. Alora MB, Arndt KA. Lasers for vascular lesions. *Cosmet Dermatol* 1998; **10**: 33–40.
8. West TB, Alster TS. Comparison of the long-pulse dye (590–595 nm) and KTP (532 nm) lasers in the treatment of facial and leg telangiectasias. *Dermatol Surg* 1999; **24**: 221–6.
9. Dover JS, Sadick NS, Goldman MP. The role of lasers and light sources in the treatment of leg veins. *Dermatol Surg* 1999; **25**: 328–36.
10. Green D. Treatment of telangiectases of the lower extremity: sclerotherapy and photothermal coagulation. *Cosmet Dermatol* 1999; **11**: 21–5.